
MicroHip: A minimally invasive procedure for total hip replacement surgery

A modified Smith-Petersen approach

M.C. MICHEL, P. WITSCHGER

Münsingen Orthopaedic Centre, Münsingen - Switzerland

ABSTRACT: *In this article we present the surgical technique of our anterior minimally invasive approach to the hip joint. This is aligned along an interneural plane and makes the approach truly minimally invasive. This technique is performed in a lateral decubitus position on a normal operating table; there is no need for a specific orthopaedic or fracture table. As leg traction is not necessary, this enables the approach to be used routinely. Most of the instruments used for this procedure are standard instruments; only the acetabular reamers and positioners are angulated and specifically designed. The angled instruments (MI – minimally invasive) are especially useful when performing hip replacement in obese patients.*

An excellent view of both the acetabulum and the proximal femur can be obtained through an incision of only 6-8cm, using this MI approach. The approach follows the interval between the tensor fascia lata muscle and the rectus muscle using a section of the anterior iliofemoral approach described by Smith-Petersen. No tendon or muscle is cut or detached. The joint capsule is split and left in place. The hip joint is not dislocated and we perform the osteotomy of the femoral neck in situ. To date we have performed over 500 MicroHip™ operations. We have not observed any nerve lesions or fractures of the trochanter. Our experience to date shows that the method we have developed allows us to operate reliably on virtually any patient. Preliminary results also show that important factors like length of stay, pain, blood loss and return to work can be reduced significantly. The MicroHip™ technique is being used by more and more different clinics all over the world and can be applied with success after suitable training. (Hip International 2006; 16 (suppl 3): S40-7)

KEY WORDS: *Hip, Hip endoprosthesis, Minimally invasive, Joint replacement, MicroHip*

INTRODUCTION

Historically, total hip replacement was considered to be a “major operation, and so requiring a major incision”. With more biological understanding, surgeons are more aware that every incision represents an additional trauma, which may lead to permanent tissue damage. This not only causes postoperative pain, thus

increasing hospitalisation and rehabilitation times, but may under some circumstances also lead to loss of fine motor skills. The significant factors are not just the length of the skin incision but also the deeper structures under the skin. Most important in this respect are undoubtedly muscles and ligaments, with the abductor muscles, gluteus medius and minimus playing a particularly central role. These structures have a major

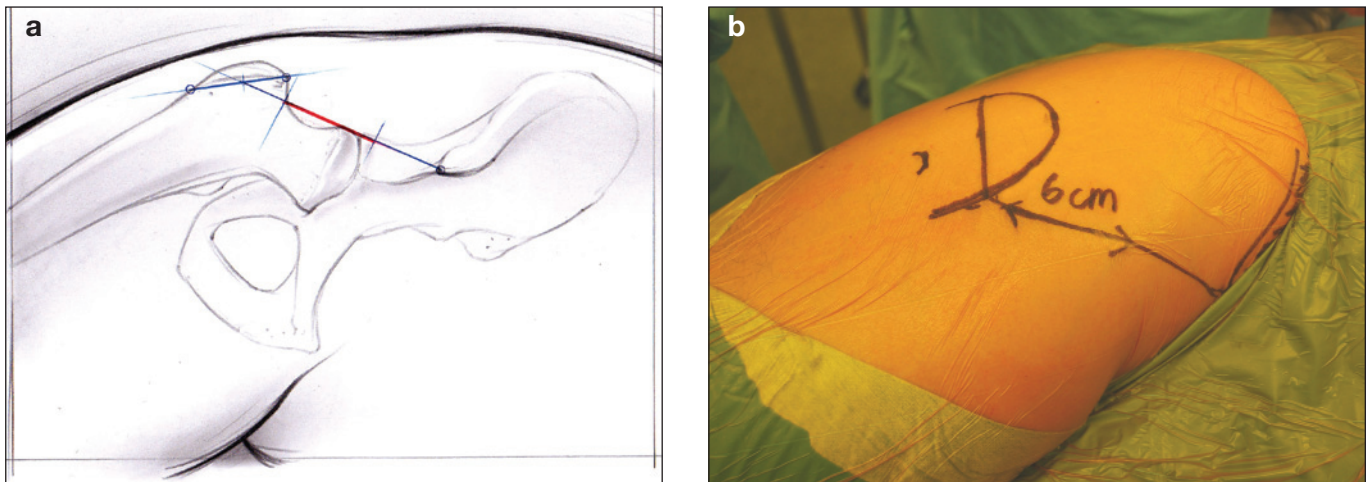


Fig. 1 - Landmarks for the incision.

influence on perception and damage to the nerve pathways must be kept to an absolute minimum.

Mini-incision total hip replacement (THR) has been pursued by various surgeons and different approaches have been described (1-3).

The ideal minimally invasive approach would not only avoid muscles and ligaments completely but would also be situated in an interneural plane, i.e. one not traversed by nerves. This represents a difference between our technique described below and most of the other mini-incision approaches described. Our technique involves using a short section of the Smith-Petersen (4) approach, which is located in the interneural plane between the tensor fascia lata and rectus/sartorius muscles, whereas the Watson-Jones approach is located between the gluteus medius and the tensor fascia lata, which is not an interneural plane. The superior gluteal nerve with a branch to the tensor fascia lata passes through this space between the gluteus medius and the tensor fascia lata muscle. As a result, every approach using the Watson-Jones interval involves a significant risk of injury to this nerve branch. This can lead to impaired functioning of the tensor fascia lata muscle, which is particularly important for persons pursuing sports such as running or cycling. This problem is avoided by the procedure. This is because, as we noted above, it is aligned along an interneural plane and does not involve any damage to ligaments or muscles. This is not only beneficial for stability but also it has been shown that nerve fibres present in the joint capsule play

a role in the fine control of the joint that should not be underestimated (5, 6). It should also not be overlooked that keeping the joint capsule greatly reduces the size of the wound surface, thus not only reducing pain but also the amount of blood loss and postoperative scar formation.

TECHNIQUE

The patient is positioned in the lateral decubitus position. The distal posterior part of the operating table is removed, so that the leg can be placed dorsally in a hyperextended position in order to present the resected neck of the femur. The patient is positioned on the remaining part of the table as close as possible to the surgeon. Both knees are slightly flexed and the patient is stabilised with a strong support on the symphysis pubis and to the sacrum. The surgeon stands ventral to the patient. Three landmarks are required:

- the tip of the greater trochanter;
- the innominate tubercle;
- the superior anterior iliac crest (Fig. 1).

The incision begins midway along the greater trochanter on its ventral edge and runs for approximately 5-7 cm in the direction of the anterior superior iliac spine.

This marks a plane that defines the femoral neck axis. Using these precise landmarks minimises the risk of iatrogenic injury of the lateral femoral cutaneous nerve

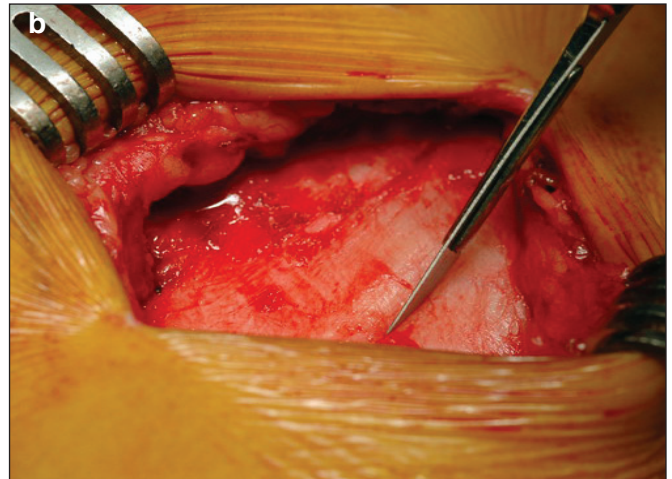
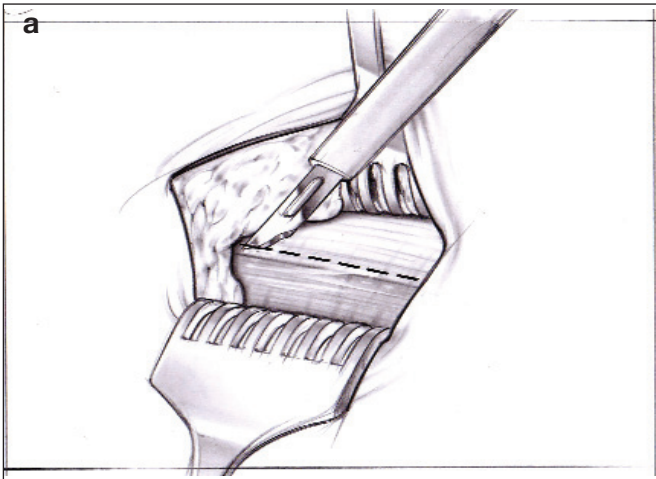


Fig. 2 - Incision of the iliotibial tract 2-5 mm medial to the underlying border of the muscular fascia.

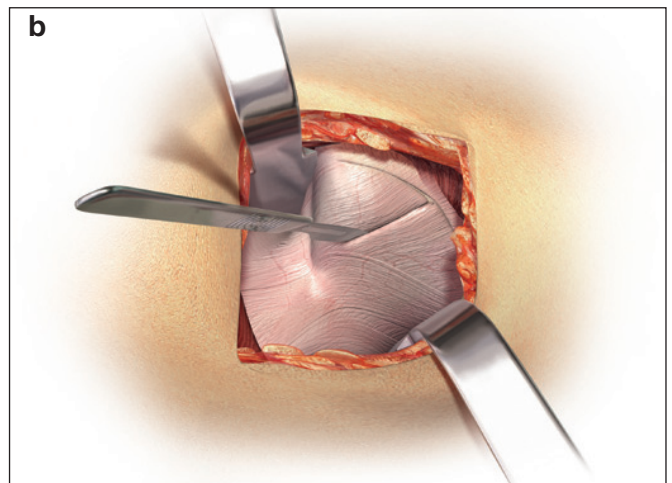
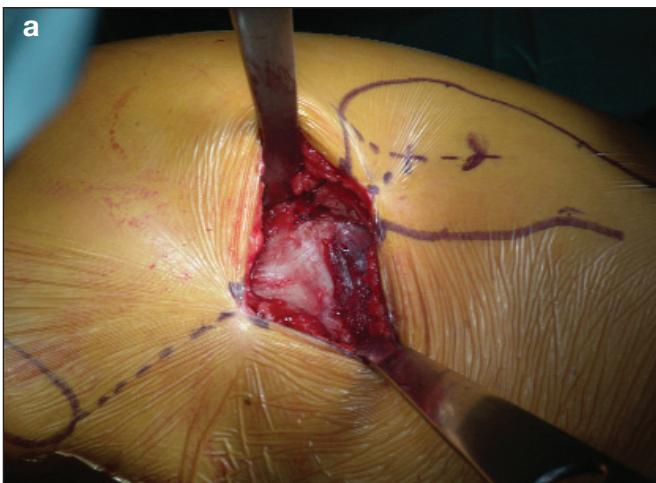


Fig. 3 - T-shape incision of the capsule.

(LCFN). The incision is lateral to the potentially dangerous area of the LFCN (7) and should not interfere with the main branches of the nerve (8) even if anatomical variability is present. The subcutaneous tissue is incised, revealing the fascial muscle plane. A minimal mobile window is created by undermining the fatty layer, sufficient to expose the capsule but not so extensive as to risk necrosis of the subcutaneous tissues. The fascia is incised approximately 2-5 mm medial to the underlying border of the fascia and the incision is extended distally and proximally in the direction of the fibres (Fig. 2). It is here that the fascia is of sufficient thickness to allow closure at the end of the procedure. Blunt dissection (using scissors) is used to separate the tensor fascia la-

ta ventrally from the fascia. The intermuscular plane is followed down to the femoral neck and the capsule. Next a straight Hohmann retractor is inserted between the tensor fascia late muscle and the sartorius muscle, with the tip coming to rest on the femoral neck and at the bottom of the greater trochanter. The tensor muscle is then retracted laterally, together with the abductor medius and minimus muscle. A second retractor is placed on the femoral calcar to retract the sartorius and rectus muscles ventrally. This will expose the capsule over the femoral neck. A T-shape capsular incision is made inferior to superior, and along the border of the greater trochanter (Fig. 3). Both flaps of the capsule are fixed with stay sutures, ready for closure at the conclu-

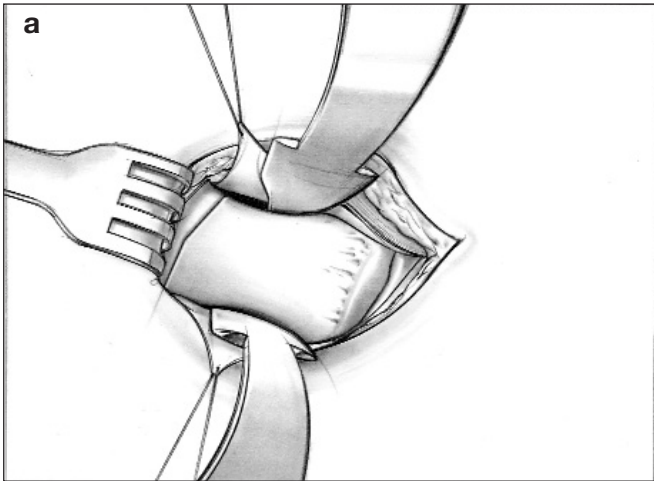


Fig. 4 - Hohmann retractors inserted beneath the capsule.

sion of the operation. Hohmann retractors can then be inserted beneath the capsule (Fig. 4) prior to osteotomising the femoral neck in accordance with preoperative planning.

The placement of the lateral retractor has to be controlled precisely, because it gives the landmark for the osteotomy. With a long narrow sawblade the femoral neck is cut without dislocating the hip (Fig. 5). After completing the osteotomy, a chisel is used to flip the femoral neck towards the front, allowing the corkscrew to be inserted axially in the femoral neck. Twisting it several times allows the head to be freed before it is extracted. To expose the acetabulum two Hohmann retractors are inserted, one medially and one laterally. A third one with a double bend can be placed distally (Fig. 6). The acetabulum is reamed out in a standard fashion using MI instruments before the cup, usually a press-fit cup, is inserted. Although standard straight instruments can be used on slim patients we always recommend using the angled MI instruments in order to familiarise the surgeons with them in straightforward cases rather than only using the angled MI instruments on obese patients who are initially more difficult to operate on. When inserting the cup great care must be taken to avoid excessive anteversion. To this end the fixation instrument must be aligned along the table axis at an inclination of 45 degrees. The course of the transverse ligament may be used as a visual cue.

Following acetabular implantation, the leg is placed

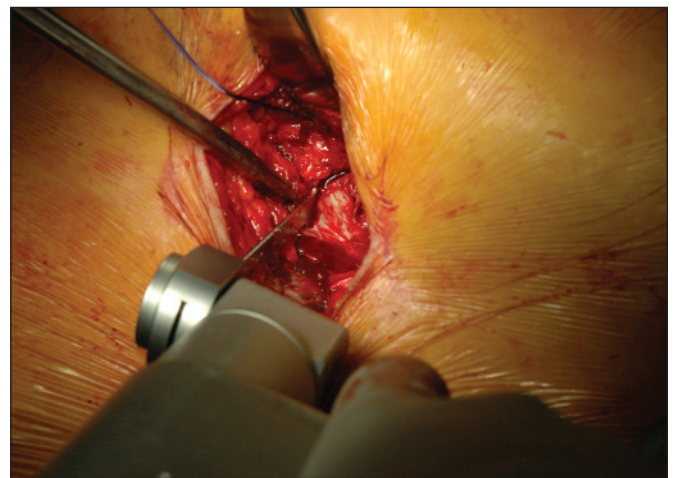
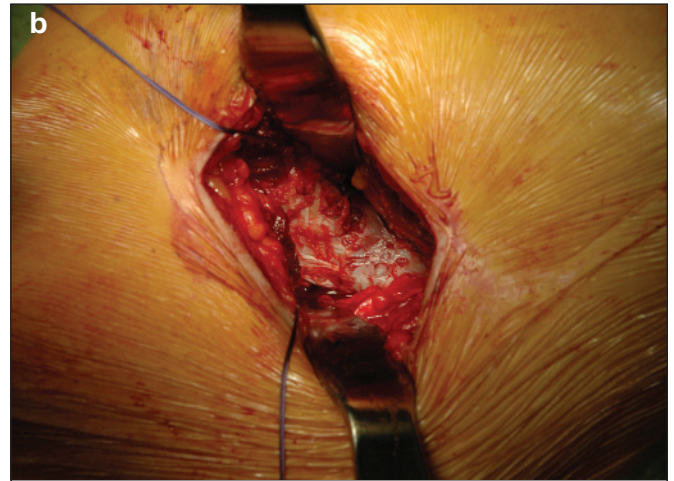


Fig. 5 - Femoral neck osteotomy.

in abduction, external rotation and hyperextension and placed in a sterile wrapping on the backside of the patient (Fig. 7). In order to evaluate the anteversion of the femoral stem it is important for the lower leg to be aligned vertically to the ground. To display the femur, a Hohmann retractor is first inserted dorso-laterally on the tip of the greater trochanter to retract the tensor, gluteus medius and minimus muscles to the lateral side. Next, another Hohmann retractor is positioned at the femoral calcar. The entire femoral entry plane must now be displayed carefully to allow the precise opening point to be determined. A sharp

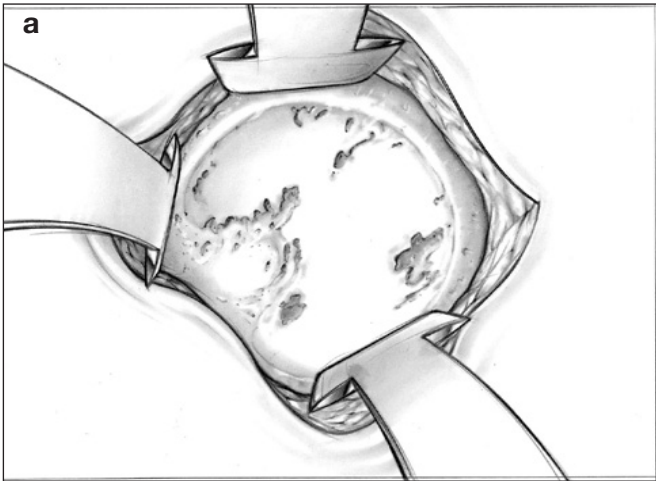


Fig. 6 - View to the acetabulum with the three retractors in place.

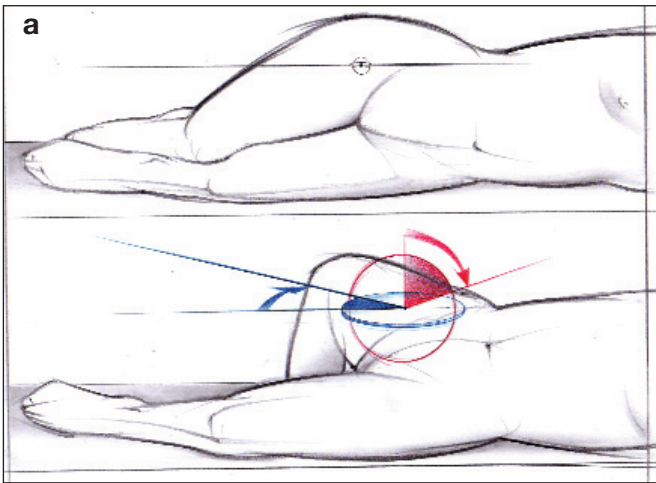
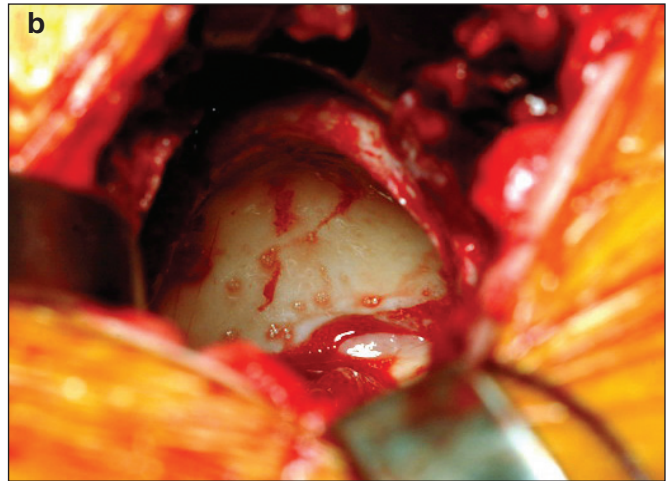
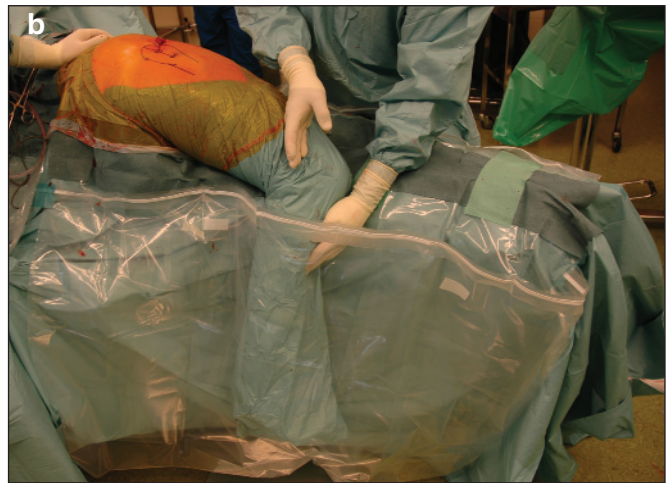

Fig. 7 - Positioning of the leg to approach the femur.



curette can be used to open the femur and then standard broaches are used (Fig. 8). The femoral prosthesis is inserted taking careful account of the antetorsion. The leg length is determined by the distance from the tip of the greater trochanter to the implant, which was precisely templated before the operation. After reduction, the joint capsule is closed using the initial stay sutures and a few extra stitches. The ilio-tibial tract is closed with continuous stitching. To get the best possible cosmetic result the skin is closed with a subcutaneous suture.

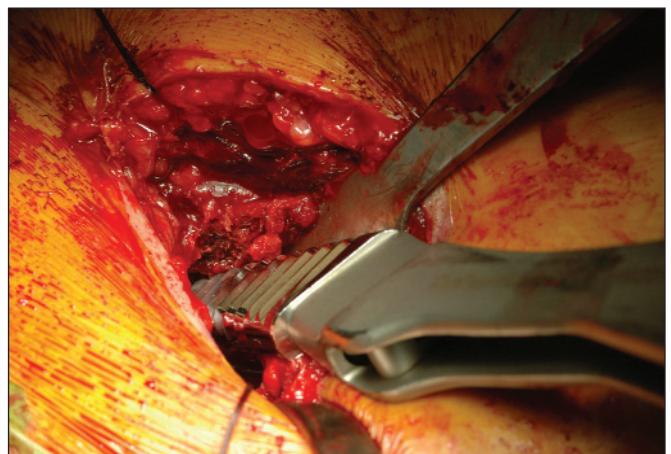


Fig. 8 - Femoral broaching.

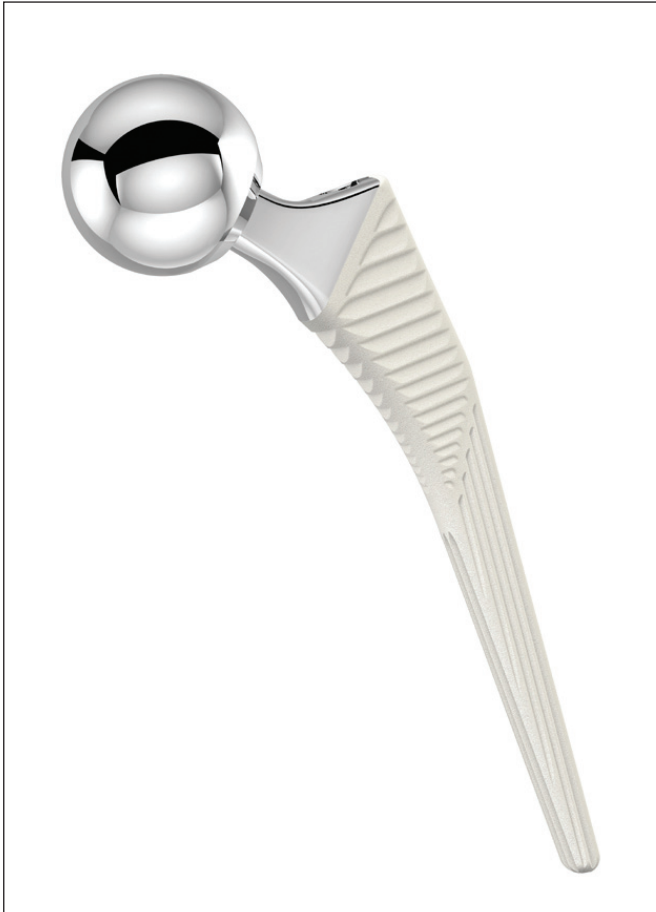

Fig. 9 - The Corail® stem.

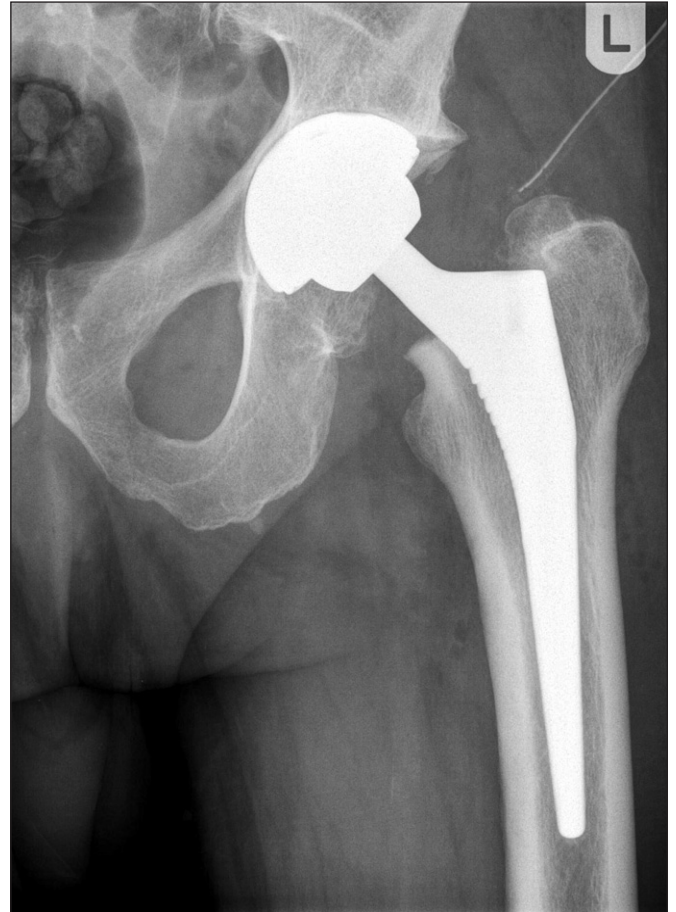

Fig. 10 - Postoperative X-ray.

DISCUSSION

To date we have performed over 500 MicroHip operations and we have not observed any nerve lesions or trochanter fractures.

The procedure takes about 45 minutes, and is performed in an interneural plane without detachment of ligaments or muscles or resection of the capsule. It is performed on a normal table using standard instruments. Our greatest initial difficulty was with the alignment of the acetabulum, but provided MicroHip technique is followed carefully it can be implanted safely in the correct orientation. Calcar fissures do not as a rule pose any problem, but they can be avoided by displaying the femur correctly in order to ensure that the right entry point is chosen.

As the acetabular exposure is excellent, inserting the cup does not pose any great challenge, and most types of cup can be positioned without difficulty. A number of essential considerations lie behind the selection of the stem. The operative technique we have developed does everything to avoid damage of the muscles, especially the abductors. It is possible, albeit more difficult, to insert a straight implant with a lateral shoulder via this approach. However, this would make little sense given that a straight implant with a lateral shoulder often has to be inserted so far into the greater trochanter that significant damage occurs to the abductor tendons. In contrast, a straight stem with a minimized lateral shoulder (Figs. 9 and 10) or a short anatomic prosthesis (Figs. 11 and 12) is preferable both in



Fig. 11 - Short anatomic prosthesis.

that it is easier to insert and in that it does not have to be inserted as far into the trochanter region; as a result it does not come into contact with the abductor tendons. A further factor we regard as important is that a hydroxyapatite-coated implant grows in significantly more rapidly, and this can certainly be advantageous in promoting a faster return to full use of the joint.

CONCLUSION

The MicroHip technique allows a total hip joint replacement to be implanted using a very short incision and without damaging the musculature. Our experience to date shows that the method we have developed allows us to operate reliably on virtually any patient. However, a prerequisite for this is suitable training. The results are often so good that it can be difficult to persuade patients that it is

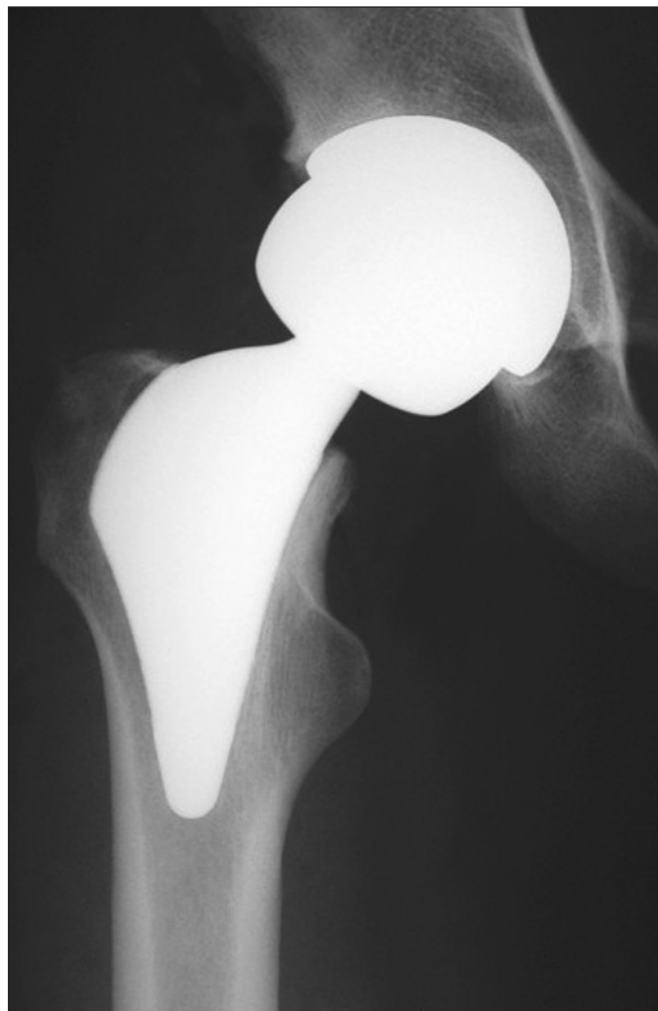

Fig. 12 - Postoperative X-ray.

important to carefully build up the loads exerted on the joint. Although postoperative pain is far less, so that early full weightbearing is possible, the biology nevertheless remains the same, and this means that the healing of the wound and related structures still takes the same time.

ACKNOWLEDGEMENTS

We would like to thank DePuy, a Johnson&Johnson Company, who made the cadaver research possible which was of pre-eminent importance in the development of this approach. No grants have been received by any party. The described work complies with the current laws of Switzerland.

Address for correspondence:

Markus C. Michel, MD

Orthopaedic Center Münsingen

Krankenhausweg 18A

CH-3110 Münsingen, Switzerland

e-mail: markus.c.michel@bluewin.ch

REFERENCES

1. Berger RA. Total hip arthroplasty using the minimally invasive two-incision approach. *Clin Orthop Relat Res* 2003; 417: 232-41.
2. Bertin KC, Rottinger H. Anterolateral mini-incision hip replacement surgery: a modified Watson-Jones approach. *Clin Orthop Relat Res* 2004; 429: 248-55.
3. Hartzband MA. Posterolateral minimal incision for total hip replacement: technique and early results. *Orthop Clin North Am* 2004; 35: 119-29.
4. Smith-Petersen MN. Approach to and exposure of the hip joint for mold arthroplasty. *J Bone Joint Surg Am* 1949; 31: 40-6.
5. He XH, Tay SS, Ling EA. Sensory nerve endings in monkey hip joint capsule: a morphological investigation. *Clin Anat* 1998; 11: 81-5.
6. Aloisi AM, Carli G, Rossi A. Response of hip joint afferent fibers to pressure and vibration in the cat. *Neurosci Lett* 1988; 90: 130-4.
7. Grothaus MC, Holt M, Mekhail AO, Ebraheim NA, Yeasting RA. Lateral femoral cutaneous nerve: an anatomic study. *Clin Orthop Relat Res* 2005; 437: 164-8.
8. Da Rocha RP, Fernandes GJ, Vengjer A, Mongon ML, Ribeiro FP, Longuinho e Silva RB. Distribution of the lateral cutaneous nerve of the thigh in the area of intramuscular injection. *Rev Assoc Med Bras* 2002; 48: 353-6.